CORONARY ANGIOGRAPHY REPORT

NAME:	Mr. Radheshyam Mittal	AGE/SEX:	58 Y / Male
I.P.D. NO.	22554	DATE	28.11.2018
I.D. NO.	98957		
REF.BY	Hospital Case		
Done By.	Dr. Ashish Mishra MD, DNB, F.A.C.C. (USA) (Cardiology)		

Clinical Diagnosis : IHD / inferior MI

Final Diagnosis : CAG –Left Main disease with Triple Vessel Disease, LAD - 70-80 % lesion. Lcx – 100 %, lesion, RCA -100 % lesion

Catheter Used : JL - 4
JR - 4

Left Main : shows – ostial 40-50 % lesion without over pressure drop

LAD : Proximal 70- 80 % lesion.

Mid – 70-80 % lesion.

Distal – No obstruction

D1 – Shows – Proximal 70-80 % lesion

LCx – Proximal shows 100 % lesion

OM2 and small **OM1** distal Lcx on filling retrogradely from left collaterals.

Collaterals from left system are filling RCA retrogradely.

RCA - Proximal – shows 100 % lesion.

LIMA – RIMA – No obstruction.

Left Subclavian artery shows 100 % flow for LIMA.

Recommendation : CABG surgery.

for
Dr. Ashish Mishra
MD, DNB, F.A.C.C. (USA)
(Cardiologist)

CHLMC/1117/CATH/78-V4

Hosp. Reg. No. 223

Name : MR. RADHE SHYAM MITTAL
Reg.No.: 98957 Age/Sex : 58 Y / MALE
IPD No.: I000022554 DOA : 28/11/2018
Consultant : RAWAT DR. V K MD (MEDICI

CHL-Medical Center
—inspiring health— UJJAIN
(A Unit of CHL Group of Hospitals)

Date 28/11/2018

Department of Interventional Cardiology

Patient's Name MITTAL RADHE SHYAM Age/Sex 58Y/M Reg. No. 98957

IPD No. 22554 Cath No 167/259/18 Done by Dr. DR MISHRA A.

REF BY: DR. GARG VIMAL MD (MEDICINE)

MD DNB FACC (USA) (CARDIOLOGIST)

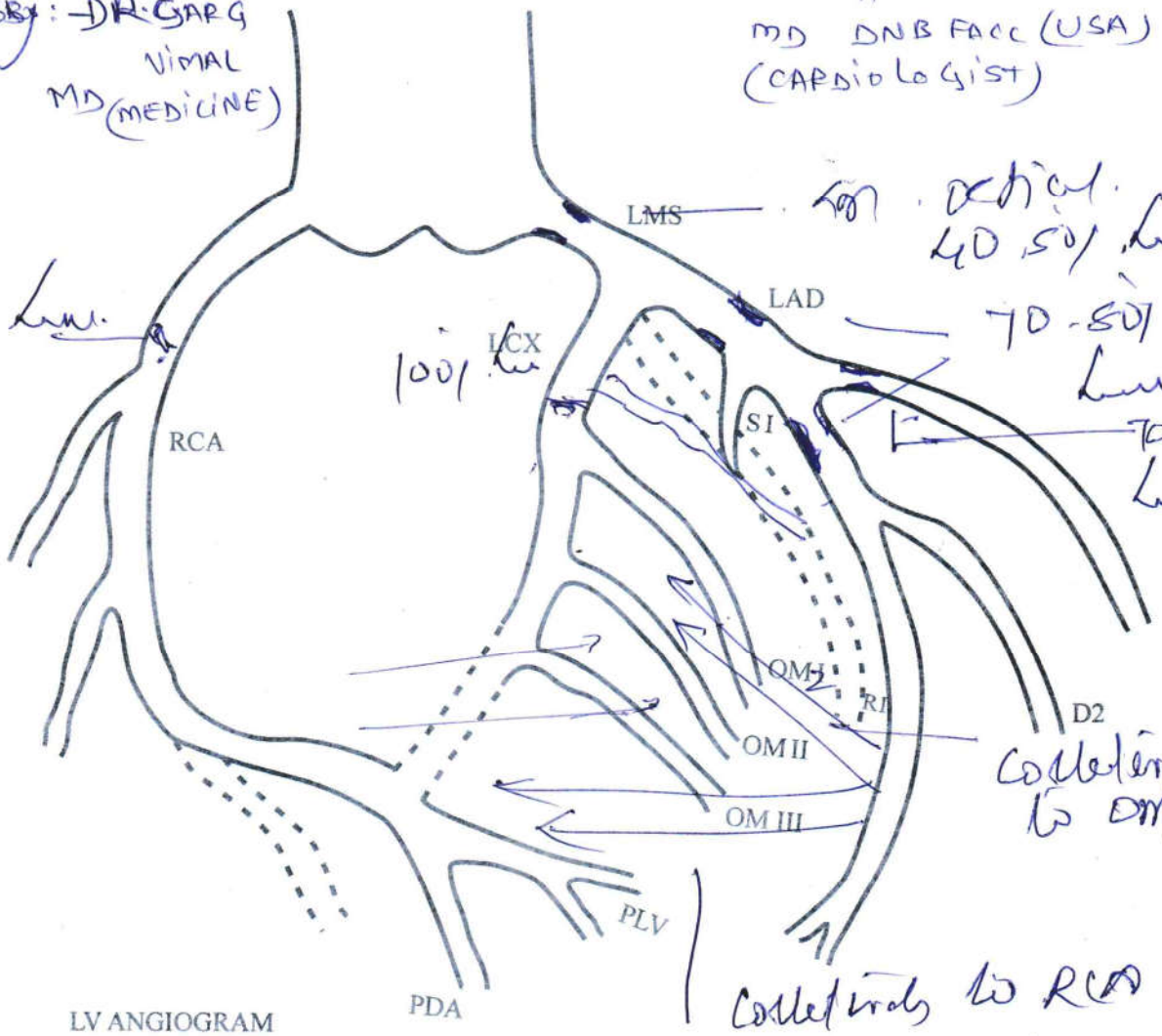

LMS 50% ostial. 40-50% Lum

LV ANGIOGRAM

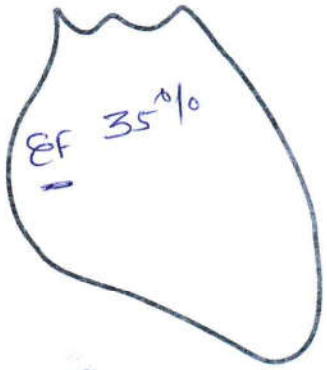

LIMA → RCA (a)

Signature of Interventional Cardiologist .....

Time .....